

CASE REPORT

Bifurcation of the Brachial Artery into Brachioradial and Brachioulnar Arteries in the Proximal Arm: Case Report and Clinical Significance

Maria Ximena Leighton^{1*}, Elizabeth Maynes¹,
Keiko Meshida², Gary Wind¹, Guinevere Granite¹

Leighton MX, Maynes E, Meshida K, et al. Bifurcation of the Brachial Artery into Brachioradial and Brachioulnar Arteries in the Proximal Arm: Case Report and Clinical Significance. *Int J Cadaver Stud Ant Var*. 2023;4(1):01-10.

Abstract

During anatomical dissection of fifty donors in the 2020 undergraduate first-year anatomy course at the Uniformed Services University of the Health Sciences, a high origin of the radial and ulnar arteries, also known as a brachioradial artery and a brachioulnar artery, was observed on the left arm of a 90 year-old White female donor. The bifurcation of the brachial artery occurred in the proximal third of the arm. The left brachioradial and left brachioulnar arteries ran superficial and medial to the biceps brachii muscle. The brachioulnar artery continued as the ulnar artery in the forearm, ran superficial and lateral to the flexor carpi ulnaris muscle, traversed the flexor retinaculum, and continued to form the superficial arterial palmar arch. The brachioradial artery ran deep to the pronator teres

muscle and continued as the radial artery in the forearm. It presented with an atypical branching pattern and was tortuous until it reached the hand. On the dorsum of the hand, the radial artery runs superficial to the first dorsal interosseous muscle, parallel to the first metacarpal bone. It also reached the palmar side of the hand in an unusual manner. Medical professionals, especially radiologists, and orthopedic and vascular surgeons, need to be aware of these variations to avoid iatrogenic injuries during routine procedures, such as venipuncture and intravenous injections. Knowledge of these variations is also vital during invasive procedures, such as elbow reconstructive surgery, percutaneous brachial catheterization, and when creating an arteriovenous fistula using the radial artery. When such variations are suspected, for example when there is family history or a positive Allen's test before a procedure, Doppler and angiogram studies are necessary.

Key Words: *Brachioulnar artery; Brachioradial artery; Brachial artery variations; Arm anatomical variations*

¹Department of Surgery, Uniformed Services University of the Health Sciences, Bethesda, MD 20814, USA

²The Henry M. Jackson Foundation for the Advancement of Military Medicine, Inc., Bethesda, MD 20814, USA

*Corresponding author: Maria Ximena Leighton, Department of Surgery, Uniformed Services University of the Health Sciences, Bethesda, MD 20814, USA, Tel: +1-301-295-9379; E-mail: maria.leighton@usuhs.edu

Received: October 21, 2022, Accepted: February 07, 2023, Published: February 28, 2023



This open-access article is distributed under the terms of the Creative Commons Attribution Non-Commercial License (CC BY-NC) (<http://creativecommons.org/licenses/by-nc/4.0/>), which permits reuse, distribution and reproduction of the article, provided that the original work is properly cited and the reuse is restricted to noncommercial purposes.

Introduction

Numerous anatomical variations of the upper limb have been described in the literature since the early 1800s, mainly found during cadaveric studies [1-3]. From the emerging literature, it is now evident that a good understanding of normal human anatomy and knowledge of the most prevalent and rarest variations is vital to all the members of the medical teams performing surgical, medical, and invasive or noninvasive radiological procedures [4]. Such as, elbow reconstructive surgery, percutaneous brachial catheterization, as well as creating an arteriovenous fistula using the radial artery (RA). Limited clinical data is available regarding the prevalence of anatomical variations found during those procedures in the upper limb. The publications are often case reports of complications or adverse surgical outcomes due to the unexpected presence of anatomical variations.

Additionally, since the late 1980s, the brachial artery (BA), and the RA, have been used for coronary angiography when the femoral approach is contraindicated which has an estimated incidence of 2% to 10% [5]. Hildick-Smith DJ et-al showed in his study of 250 patients who underwent diagnostic coronary angiography from the RA since the femoral approach was contraindicated has a 92% success, the main reason for failure was unsuccessful radial artery access, they also concluded that there is a need to demonstrate dual palmar vascular supply [6].

In a recent study of 1195 patients, Gang N, *et al.* found anatomical variations in 117 (9.7%) patients during transradial coronary procedures. High origin of the RA was the most common variation. They demonstrated that transradial navigation difficulties and failures were

significantly higher in patients with anatomical variations versus patients without them with, 42.7% versus 2.0% $p < 0.001$ and 9.4% versus 0.9%, $p < 0.001$ respectively [7].

The BA is the continuation of the axillary artery (AXA) after it passes the inferior border of the teres major muscle. The BA classically runs deep to the median nerve (MN) in the arm. It gives off the deep BA (profunda brachii artery). At elbow level, the BA predominately passes laterally to MN and medially to the biceps brachii muscle tendon (BBMT) where it bifurcates into the RA and ulnar artery (UA) at the level of the cubital fossa. The RA runs typically under the brachioradialis muscle and lateral to the flexor carpi radialis muscle. It supplies the radial side of the flexor and extensor muscles in the forearm. When it reaches the wrist, before going under the tendons of the abductor pollicis longus muscle and extensor pollicis brevis muscle, it gives off the superficial palmar branch, which will join the superficial palmar arch from the UA. The UA is the larger terminal branch of the BA. It usually gives off the common interosseous artery (CIA), the anterior ulnar recurrent artery (AURA), and the posterior ulnar recurrent artery (PURA). The UA runs distally between the second and third layer of the flexor compartment of the forearm. At the wrist level, the UA crosses superficial to the flexor retinaculum to reach the hand, then it provides the deep palmar branch and continues as the superficial palmar branch to join the superficial palmar arch.

In the literature, variations in the BA are common. They range between 0.5-20% [8-10]. Most of the variations occurring in the arm can be classified based on the origin of the BA and its terminal branches, as well as the bifurcation level of the BA and its relationship with the

MN [11,12]. Persistent embryological arterial patterns and even the absence of this artery have also been described in the literature [13]. One of the most frequent variations described in the arm is the high origin of the RA, this was found in 14.2 % in McCormack's study [1] originating even directly from the AXA [14-16].

Secondly, is the superficial ulnar artery (SUA) with a frequency up to 7% [17,18]. The high bifurcation of the BA in the arm is a less frequent variation, it was only found in 0.5 % in 202 cadavers studied by Bertolazzo in 1981, [1] and when it does occur, it is often present in the middle third of the arm [19]. When the BA bifurcates at a higher level, its terminal branches are called the brachioradial artery (BRA) and the brachioulnar artery (BUA), which become the RA and UA in the forearm [14,19].

The cubital fossa is another important area of arterial variations in the upper limb with significant clinical implications [14,19]. Arteries from these variations could run superficially, even subcutaneously, making them more prone to trauma and iatrogenic injuries, such as being mistaken for veins in simple and frequent procedures like venipunctures. Variations can be found more frequently unilaterally than bilaterally [14,20-22]. Additionally, different variations can be found in each limb [19].

Arterial variations in the forearm are less frequent than in the cubital fossa region. They are in relation to the RA, UA and/or persistence of embryological arteries, such as the median artery [1,19]. Variations in the course, branching, and distribution of the previously mentioned arteries have been widely described in the literature [1-3,8-13,17-19,23]. For instance, the superficial RA, which travels over the abductor pollicis longus tendon (APLT) and extensor pollicis brevis tendon (EPBT) in the

wrist region known as the anatomical snuffbox, has an incidence of approximately 0.5% [19]. Interestingly, duplication of the RA is extremely rare (0.02%), and an actual duplication has only been described by Kadanoff and Balkansy in 1966 [24]. The absence of the RA has been reported with a frequency of less than 0.03% [19]. Duplications of the UA have often been described as associated with the presence of superficial brachial ulnar artery (SBUA) [19]. The absence of the UA has not been found in large studies, such as the study from McCormack *et al.* (1953), which included 750 cadavers [1]. Its absence has only been described in the literature in three case reports [25-27]. The absence of the UA is estimated to be less than 0.015% [19].

The case presented in this article is an example of variations in the arm, cubital fossa, forearm and hand. Even more interesting, some variations presented here have not been found in the literature. In this case, also the BRA and BUA arteries did not entirely follow any of the patterns described in the literature [1,19,23].

Case Report

During anatomical dissection of fifty cadavers in the 2020 undergraduate first-year medical school human anatomy course at the Uniformed Services University of the Health Sciences, the presence of a left BRA and a left BUA was observed in a 90-year-old White female donor. The bifurcation of the BA occurred in the proximal third of the arm. The bifurcation was located approximately two centimeters (cm) after the BA passed the inferior border of the teres major muscle, transitioning from the AXA to the BA and giving off the deep BA. The left BRA and left BUA ran superficial and medial to the BBMT and deep to the MN (Figures 1, 2a and 2b).

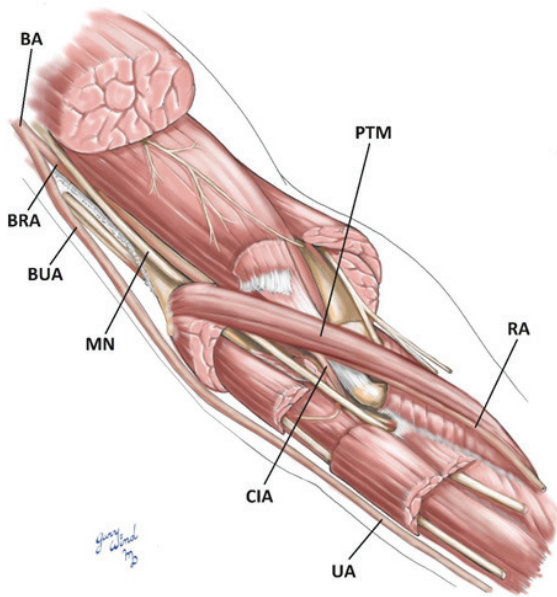


Figure 1) Illustrative schematic showing the high bifurcation of the Brachial artery into the Brachioradial and Brachioulnar arteries in the proximal arm, their course in the elbow area, and the Brachioradial artery in the cubital fossa as it continues as Radial artery, and it gives off the Common interosseous artery. The Ulnar artery runs subcutaneously at the elbow and forearm.

BA: Brachial Artery; BRA: Brachioradial Artery; BUA: Brachioulnar Artery; CIA: Common Interosseous Artery; BRA: brachioradial Artery; MN: Median Nerve; PTM: Pronator Teres Muscle; UA: Ulnar Artery; RA: Radial Artery; CIA: Common Interosseous Artery.

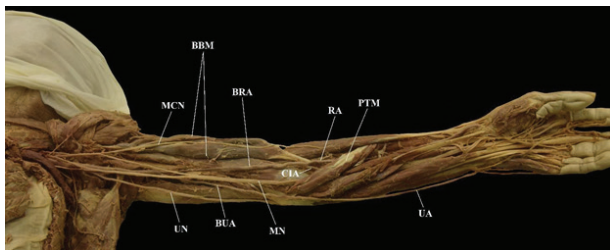


Figure 2a) Left upper limb showing the high split of the brachial artery in the proximal arm.

BBM: Biceps Brachii Muscle; BRA: Brachioradial Artery; BUA: Brachioulnar Artery; MN: Median nerve; CIA: Common Interosseous Artery; MCN: Musculocutaneous nerve; PTM: Pronator Teres Muscle; RA: Radial Artery; UA: Ulnar Artery; UN: Ulnar Nerve.

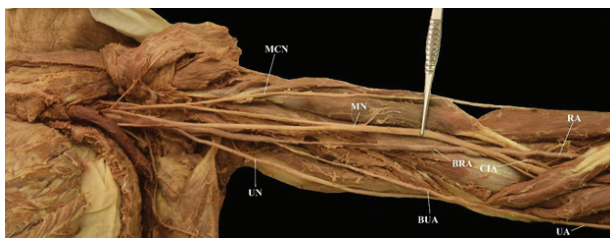


Figure 2b) Left upper limb. The Median nerve is lifted to better display the high split of the Brachial artery in the proximal arm.

MCN: Musculocutaneous Nerve; UN: Ulnar Nerve; MN: Median Nerve; BUA: Brachioulnar Artery; CIA: Common Interosseous Artery; RA: Radial Artery; UA: Ulnar Artery.

The left BUA had significantly lower caliber. At the region of the elbow, the left BUA ran superficial to the bicipital aponeurosis, crossed the cubital fossa without providing the AURA and PURA and became the UA in the forearm. The UA then ran superficial and lateral to the flexor carpi ulnaris muscle, just subcutaneously in the forearm, without giving off any branches until it reached the wrist (Figure 2a). At the wrist, it traversed the flexor retinaculum and continued to form the superficial arterial palmar arch after giving a robust deep palmar branch (DPB). The left BRA at the level of the elbow had a unique course. It ran deep to the pronator teres muscle (PTM) and had an atypical branching pattern (Figure 2a). Within the cubital fossa, the BRA gave off the CIA, which provided the AURA and PURA, and then became the RA in the forearm. The RA was very tortuous as it traveled down the forearm, and it was the main arterial supply of the forearm. After crossing under the extensor tendons of the thumb, the RA gave off a robust dorsal metacarpal branch (DCB), which ended in a robust second dorsal metacarpal artery (SDMA) (Figures 3 and 4).

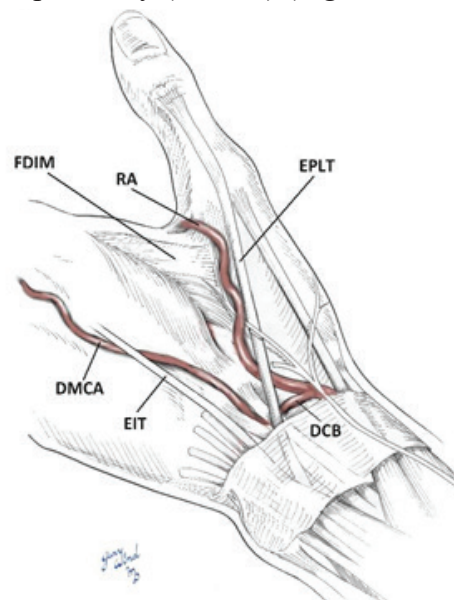


Figure 3) Illustrative schematic of the dorsum of the hand. This shows the dorsal radial artery running close to the extensor pollicis longus tendon and superficial to the first dorsal interosseous muscle, and the robust dorsal metacarpal artery traveling to the second web space.

DMCA: Dorsal Metacarpal Artery; RA: Radial Artery; DCB: Dorsal Carpal Branch; DMCA: Dorsal Metacarpal Artery; EIT: Extensor Indicis Tendon; EPLT: Extensor Pollicis Longus Tendon; EIT: Extensor Indicis Tendon; FDIM: First Dorsal Interosseous Muscle.

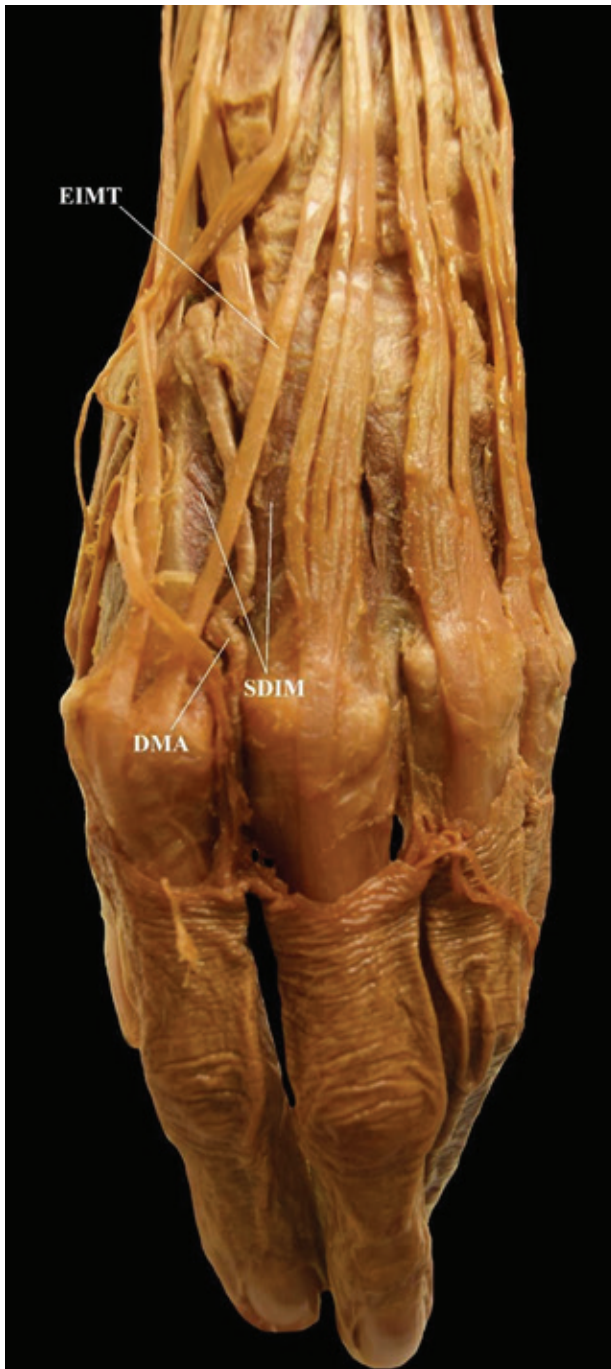

Figure 4) Image highlighting the pathway of the Dorsal metacarpal artery onto the dorsum of the hand.

DMA: Dorsal Metacarpal Artery; EIMT: Extensor Indicis Muscle Tendon; SDIM: Second Dorsal Interosseous Muscle

After providing the DMCB, the RA runs superficial to the first interosseous muscle (FDIM), parallel to the first metacarpal bone (Figure 5). Then it traveled to the palmar side just under the skin and gave off a small palmar branch to contribute to the superficial palmar arch (Figure 6).

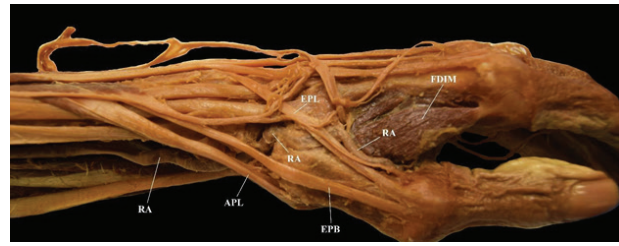


Figure 5) Radial artery passing through the snuff box and taking an unusual path to reach the palm of the hand.

RA: Radial Artery; EPLT: Extensor Pollicis Longus Tendon; APLT: Abductor Pollicis Longus Tendon; EPBT: Extensor Pollicis Brevis Tendon; FDIM: First Dorsal Interosseous Muscle.

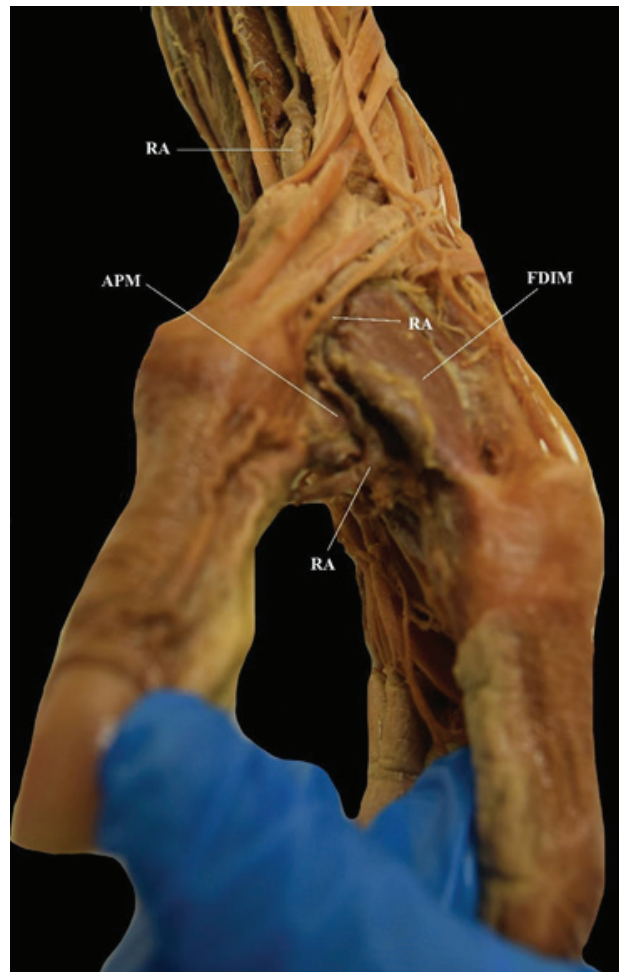


Figure 6) Radial artery after passing through the snuff box and taking an unusual path to reach the palm of the hand.

RA: Radial Artery; APM: Adductor Pollicis Muscle; FDIM: First Dorsal Interosseous Muscle.

Discussion

Arterial variations in the upper limb are frequently found and are usually asymptomatic. Unfortunately, most of the human anatomy books, including clinical human anatomy books, only mention the most common variations and fail to include rare, but clinically important, variations. Usually, there is also no reference to associated variations. Additionally, it is often difficult to find in the literature publications where multiple variations are described as in this case.

Throughout the years, several different criteria have been used to classify these variations [1,10,19,23,28] and different terminology has been used to refer to the same variation [18]. All the classifications lack a detailed description of each of the patterns throughout their course in the arm, and forearm, and often do not mention the wrist or the hand. The lack of information has made it difficult to know the actual frequencies of numerous clinically important variations.

By using the five patterns for a high BA bifurcation described in Bergman *et al.* (1988)'s book entitled "Compendium of Human Anatomic Variation", the high bifurcation presented here in our case study could be classified as pattern B (Figure 7) where the BRA is referenced as the 'radial interosseous trunk' and gives off the CIA [11]. Still, the BUA did not follow the course described in pattern B, where the AURA and PURA branch off this artery. In our case, both the AURA and PURA branched from the CIA. In addition, this pattern does not mention the possibility of one of the arteries running subcutaneously, as it does in our case. Furthermore, our case did not fit any of the newer patterns described in the literature [23].

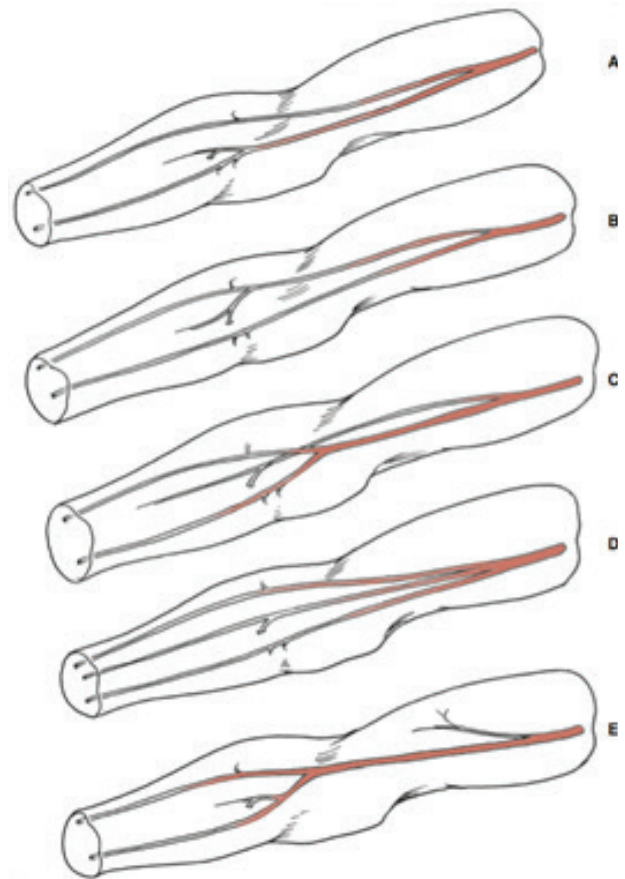


Figure 7) Illustrative schematic of the five patterns of early brachial artery branching.

A: Radial and Ulnar common interosseous trunks; B: Ulnar and Radial common interosseous trunks; C: Common interosseous or persistent median artery and radioulnar trunk; D: Radial, Ulnar, and Common interosseous trunks; E: A normal brachial artery with a long, thin aberrant branch that runs superficial to the median nerve and ends in the biceps brachii muscle.

An additional important item of note was the course of the RA after passing through the snuff box. The RA ran subcutaneously on top of the FDIM and then over the adductor pollicis brevis muscle. This course has not been found to be described in the literature. The dorsal carpal branch gave a robust second dorsal metacarpal artery, which has only been described in one publication [29] but our case differed from this one in that the second dorsal metacarpal was the only DMCA present.

Several of the variations described in the literature were most likely asymptomatic and were found postmortem during cadaveric

dissections. Nevertheless, if these patients had a traumatic injury, a medical procedure or surgery with a negative outcome, we could know the severity and potential risk of having such variations.

Recently, more data has been published on variations found when patients have undergone medical, radiological and/or surgical procedures that put the patient at risk of several complications [5-7,30-35]. Cavolli and Raif *et al.* (2007) reported a case where a patient undergoing transradial cardiac catheterization presented a complication during the procedure which required extensive vascular exposure to explore the arteries involved [5]. They found a variation on the BA, which was the cause of the problem [5]. Kian *et al.* (2011) showed that a high BA bifurcation can decrease the functional patency of an arteriovenous (AV) fistula and increase the failure rate [30].

The radial forearm free flap (RFFF) was introduced in 1981 by Dr. Yang and his group [33]. It has become the pillar for reconstructive surgeries, especially oral and oropharyngeal. Recent publications have shown the importance of the knowledge of the possible anatomical variations in the RA in the arm when planning this procedure [34,35]. Staebler *et al.* (2020) published two cases of RA anomalies discovered during elevation of an RFFF [34]. They demonstrated that Allen's test, which is commonly used when assessing the suitability of the radial forearm skin for a free flap, may not be accurate in the presence of RA abnormality. Similar to our case, Shama *et al.* (2020) presented a case report during a RFFF harvesting where they found the RA traveling under the PTM [35]. In Shama *et al.* (2020)'s case, the pre-surgical Allen's test was negative.

They also noted this variation has been reported only three times in the literature [25-27].

Procedures as simple as placing a cast in the wrist and forearm for a wrist fracture could have placed the hand circulation at risk in the donor described in our case report. Also, during venipuncture, the UA, which was subcutaneously at the elbow, could have been mistaken for a vein. Drugs treatments could have been injected with an immediate detrimental effect and/or have led to clinically significant sequelae, including paresthesia, severe pain, motor dysfunction, compartment syndrome, gangrene, and the risk of limb loss.

Embryology

In his "Developmental Anatomy" book, Arey (1957) describes six explanations for the anatomic variations in the blood vessels of the upper limb: 1) the choice of unusual paths in the primitive vascular plexus, 2) the persistence of vessels which are normally obliterated, 3) the disappearance of vessels, which are normally retained, 4) an incomplete development, 5) the fusion and absorption of parts which are normally distinct, and 6) a combination of factors leading to an atypical pattern normally encountered [36].

Rodriguez-Niedenfuhr *et al.* (2001) studied 112 human embryos (a total of 224 upper limbs) [37]. They demonstrated that arterial variations can be seen from stage 17 (41 days) to 23 (56 days). Based on these findings, and their previous publications based on human adults, they concluded that the development of the arterial pattern in the human upper limb occurs by a combined process. An initial capillary network expands into a limb bud (stage 12).

Simultaneously, the proximal parts of the network originating from the dorsal aorta start to enlarge and begin the differentiation of the arterial wall (stage 13). Rodriguez-Niedenfuhr *et al.* (2001) suggested that the persistence, enlargement and differentiation of capillaries creating the initial capillary plexus, which would normally remain in a capillary state or even regress, originate arterial variations of the final arterial pattern, rather than the sprouting of aberrant vessels suggested previously in the literature [37].

Singh (2013) in his book *Clinical Embryology* [38], states that each upper limb of the embryo is supplied by an axis artery (AA) that is derived from the seventh intersegmental (subclavian) artery. The AA develops distally along the ventral axial line and terminates in a palmar capillary plexus in the hand. The main trunk of the AA forms the AXA, the BA, the Anterior Interosseous Artery (AIA), and the deep palmar arch. develop later. A branch from the main trunk passes dorsally to form the posterior interosseous Artery (PIA). The RA and UA are the last arteries to develop as well as their branches. At the beginning, both arise more proximally and later, they make a new connection with the main artery, and the proximal origins of these arteries regress. A high BA bifurcation could be explained by the proximal origins not regressing and the arteries not reconnecting with the main trunk.

Conclusion

To avoid iatrogenic injuries and increase the procedural success rate, it is necessary to understand normal human anatomy and the knowledge of possible anatomical variations that could be encountered in common and

specialized medical, surgical, and invasive and non-invasive radiological procedures. When such variations are suspected, Doppler and angiogram studies are essential. Furthermore, when one variation is found, it is wise to suspect that additional variations may be present. This will ensure that the arterial supply for the rest of the limb, especially the hand, will be maintained.

Acknowledgment

We would like to thank the families of our donors for their beneficent contribution. Without their generosity, this article would not have been possible. We would also like to thank Ms. Sara Chae for assisting us in our literature review.

Disclaimer

The opinions or assertions contained herein are the private ones of the author/speaker and are not to be construed as official or reflecting the views of the Department of Defense, the Uniformed Services University of the Health Sciences or any other agency of the U.S. Government.

The contents of this presentation are the sole responsibility of the author(s) and do not necessarily reflect the views, opinions or policies of Uniformed Services University of the Health Sciences (USUHS), The Henry M. Jackson Foundation for the Advancement of Military Medicine, Inc., the Department of Defense (DoD) or the Departments of the Army, Navy, or Air Force. Mention of trade names, commercial products, or organizations does not imply endorsement by the U.S. Government.

References

- McCormack LJ, Caudwell E W, Anson BJ. Brachial and antebrachial arterial patterns, a study of 750 extremities. *Surg Gynecol Obstet.* 1953;96:43-54.
- Jayasree CH, Reddy C. A cadaveric study on variations in brachial artery- an anatomical perspective. *Perspect Med Res.* 2017;5:20-32
- Chakravarthi KK, Siddaraju KS, Venumadhav N, et al. Anatomical variations of brachial artery - its morphology, embryogenesis and clinical implications. *J Clin Diagn Res.* 2014;8:AC17-20.
- Hegazy AA. Human Anatomy: An inlet of medicine and surgery. *IJHA.* 2019;1:1.
- Cavolli R, Eryilmaz S, Kaya B, et al. Report of the anatomic variation of the brachial artery in a patient undergoing transradial cardiac catheterization. *J Vasc Nurs.* 2007;25:19-20.
- Hildick-Smith DJR, Lowe MD, Walsh JT, et al. Coronary angiography from the radial artery- experience, complications and limitations. *Int J Cardiol.* 1998;64:231-9.
- Gang N, Sagar P, Kapoor A, et al. Arterial anomalies of the upper limb and their influence on transradial coronary procedures. *J Invasive Cardiol.* 2021;33:E165-71.
- Akamatusa FE, Saleh SO, Andrade M, et al. Brachial artery variation - a rare pattern. *J Morphol Sci.* 2013;30:182-5.
- Casal D, Pais D, Toscano T, et al. A rare variant of the ulnar artery with important clinical implications: a case report. *BMC Res Notes.* 2012;5:560.
- Bagal G, Takale S. A cadaveric study on division of brachial artery with embryological basis and clinical significance. *JMSCR.* 2015;3:8708-12.
- Bergman RA, Thompson SA, Afifi AK, et al. *Compendium of human anatomic variation, text, atlas and world literature.* Urban and Schwarzenberg, Munich. 1988.
- Kumar V, Rathnakar P. Unilateral high division of brachial artery: a case report and literature review. *NUJHS.* 2014;4:115-8.
- Ciervo A, Kahn M, Pangilinan AJ, et al. Absence of brachial artery: report of a rare human variation and review of upper extremity arterial anomalies. *ESVS.* 2001;33:191-4.
- Haladaj R, Wysiadecki G, Dudkiewicz Z, et al. The high origin of the radial artery (brachioradial artery): its anatomical variations, clinical significance, and contribution to the blood supply of the hand. *Biomed Res Int.* 2018;2018:1520929.
- Agarwal S, Lalwani R, Babu R. High origin of radial artery: a comparative, anatomical and embryological consideration. *Int J Res Med Sci.* 2016;4:3295-8.
- Saraawathi P, Christy AJ, Sainath S. High bifurcation of the radial and ulnar artery from the brachial artery: case report. *Int J Anat Var.* 2017;10:26-7.
- Reddy S, Vollala V. The superficial ulnar artery: development and clinical significance. *J Vasc Bras.* 2007;6:285-8.
- Senanayake KJ, Salgado S, Rathnayake MJ, et al. A rare variant of the superficial ulnar artery, and its clinical implications: a case report. *J Med Case Reports.* 2007;1:128.
- Rodriguez-Niedenfu M, Vasquez T, Near L, et al. Variations of the arterial pattern in the upper limb revisited: a morphological and statistical study, with a review of the literature. *J Anat.* 2001;199:547-66.

20. Mohammadi A, Alizadeh R, Rajai M, et al. Case report: the unilateral high bifurcation of the brachial artery. *Anat Sci J*. 2020;17:43-6.
21. Roy T, Roy H, Ghosal T, et al. Unilateral variations in upper limb arterial system: a case report with literature review. *J Clin Diagn Res*. 2014;8:150-2.
22. Balasubramanian R, Subramaniam C, Virupaxi RD, et al. Unilateral higher division of the brachial artery. *J Sci Soc*. 2018;45:43-6.
23. Tubbs RS, Shoja M, Loukas M. Bergman's comprehensive encyclopedia of human anatomic variation. Wiley Blackwell, Hoboken, New Jersey. 2016.
24. Kadanoff D, Balkansky G. Zwei fälle mit seltenen varietäten der arterien der oberen extremität. *Anat Anz*. 1966;118:289-96.
25. Lee JH, Ju RK, Jun YJ, et al. A rare case of bilateral absence of distal ulnar artery. *Plast Aesthet Res*. 2015;2:79-80.
26. Zhao X, Ma X, Guo L. Congenital absence of the ulnar artery. *J Hand Surg*. 2016;41:773-4.
27. Taylor BA, Alzhari F, Levi E. Absence of ulnar artery inflow detected by Allen's test prior to radial forearm free flap. *Plast Reconstr Sur Glob Open*. 2017;5:1299.
28. Keen JA. A study of the arterial variations in the limbs with special reference to symmetry of vascular patterns. *Am J Ant*. 1961;108:245-61.
29. Bianchi HF, Vargas CA, Ottone NE. Unusual ending of the second dorsal metacarpal artery as proper palmar digital arteries. *Folia Morphol*. 2017;77:393-6.
30. Kian K, Shapiro A, Loay S, et al. High brachial artery bifurcation: clinical considerations and practical implications for an arteriovenous access. *Semin Dial*. 2012;25:244-7.
31. Narsinh KH, Mirza MH, Duvvuri M, et al. Radial artery access anatomy: considerations for neuroendovascular procedures. *J Neuro Intervent Surg*. 2021;13:1139-44.
32. Bulum J, Ostojic Z, Ernst A, et al. Frequency of anatomic variations of radial artery in patients undergoing transradial heart catheterization. *Cardiol Croat*. 2014;9:177.
33. Yang GF, Chen PJ, Gao YZ, et al. Forearm free skin flap transplantation: a report of 56 cases. *Br J Plast Surg*. 1982;50:162-5.
34. Staebler MH, Anzalone CL, Price DL. The anomalous radial artery: a rare vascular variant and its implications in radial forearm free tissue transfer. *Craniomaxillofac Trauma Reconstr*. 2020;13:215-8.
35. Shama M, Danan D, Salem A, et al. Vascular anomalies of radial forearm free flap: Systematic approach to avoid complications. *Otolaryngol Case Rep*. 2020;17:100251.
36. Arey LB. *Development anatomy*. (7th edn), WB Saunders Company, Philadelphia. 1974.
37. Rodriguez-Niedenfur M, Burton GJ, Deu J, et al. Development of the arterial pattern in the upper limb of staged human embryos: normal development and anatomic variations. *J Anat*. 2001;199:407-17.
38. Singh V. *Textbook of clinical embryology*. Elsevier, India. 2017.