

## CASE REPORT

## Sternalis Muscle: A Case Report and Literature Review

Lucas Albuquerque Chinelatto<sup>1\*</sup>, Flavio Carneiro Hojaij<sup>2</sup>,  
Jade Verena Terra Carvalho<sup>3</sup>, Gabriela da Silva Cabral<sup>4</sup>,  
Luana Queila Rodrigues<sup>5</sup>, Flavia Emi Akamatsu<sup>6</sup>, Luiz Alfredo Jacomo<sup>7</sup>

Chinelatto LA, Hojaij FC, Carvalho JVT, et al. Sternalis Muscle: A Case Report and Literature Review. *Int J Cadaver Stud Ant Var.* 2023;4(1):32-37.

## Abstract

**Introduction and Objective:** The sternalis muscle (rectus sternalis muscle) is a rare anatomical variation found on the anterior chest wall with . This study's objective was to make a narrative review of the anatomical and epidemiological aspects of the sternalis muscle, as well as to present its finding in one of this case report.

**Materials and Methods:** This study consisted of a literature review using Pubmed and Latin American and Caribbean Health Sciences

Literature platforms. Articles were analyzed regarding incidence, laterality, action, innervation, and vascularization of the sternalis muscle. We also present a case report based on a cadaveric dissection of the Hospital das Clínicas, Faculty of Medicine, University of São Paulo.

**Results:** Our review included 22 articles. The anatomical variation incidence ranged from 1.96% to 5.55%, with a higher predominance of a bilateral presentation. The action of the sternalis muscle is predominantly accessory and there are divergences in the literature regarding its innervation and vascularization. Our case reports documents the finding of a unilateral sternal muscle in the left paramedian line inserted in both sternocleidomastoid muscles, in a 88 years old, black, female cadaver.

<sup>1</sup>Bachelor of Medicine, Faculdade de Medicina da Universidade de São Paulo (FMUSP), São Paulo, Brazil

<sup>2</sup>Full Professor, Head and Neck Surgeon from Beneficiencia Portuguesa de São Paulo, LIM 02 - Departamento de Cirurgia, Faculdade de Medicina da Universidade de São Paulo, São Paulo, Brazil

<sup>3</sup>Medical Student, Universidade Nove de Julho - Campus Vergueiro, São Paulo, Brazil

<sup>4</sup>Medical Student, Universidade Nove de Julho - Campus Mauá, São Paulo, Brazil

<sup>5</sup>Dental Student, Universidade Cidade de São Paulo, São Paulo, Brazil

<sup>6</sup>Assistant Professor, LIM 02-Departamento de Cirurgia, Faculdade de Medicina da Universidade de São Paulo (FMUSP), São Paulo, Brazil

<sup>7</sup>Full Professor, LIM 02-Departamento de Cirurgia, Faculdade de Medicina da Universidade de São Paulo (FMUSP), São Paulo, Brazil

\*Corresponding author: Lucas Albuquerque Chinelatto, Bachelor of Medicine, Faculdade de Medicina da Universidade de São Paulo (FMUSP), São Paulo/Brazil, Tel: +551130618277; E-mail: l.chinelatto@fm.usp.br

Received: April 01, 2023, Accepted: May 02, 2023, 2023, Published: May 17, 2023



**Conclusion:** The sternalis muscle has a small incidence in the Brazilian, Indian and American population and it is usually bilateral. The anatomical knowledge of this muscle is important to prevent it from being confused with other structures commonly found in the chest and cervical region.

**Significance/Implication:** The importance of sternalis muscle cannot be overlooked

due to possible misinterpretations in imaging and its possible influence on mastectomies. Moreover, it can be used as a flap in head and neck reconstructions. Wider case series are necessary for a better definition of its irrigation and innervation.

**Key Words:** *Sternalis muscle; Sternal muscle; Anatomy; Variation; Chest variation*

## Introduction

The sternalis muscle is a rare anatomical variation found on the anterior chest wall. It is described as a paraesternal muscle, with vertically oriented fibers. Its origin is located in the clavicular head at the sternoclavicular joint and its insertion on the lower costal cartilages (5<sup>th</sup>-7<sup>th</sup> ribs) [1-7].

It was first reported in the 17<sup>th</sup> century, by Cabrol in his book *Anatomes Elenchus Accuratissimus*. In the literature, the sternalis muscle can also be referred to as episternalis, presternalis, and sternalia brutorum [1]. There is controversy in the literature related to the influence of sex and race on its prevalence [2,3].

Knowledge of this muscle variation among surgeons and radiologists is essential, because it can be seen as an abnormal nodule in a mammogram or CT scan [4]. The study of this anatomical variation is fundamental, so that the muscle is not confused with a tumor. Moreover, this muscle, when present, can be used as a flap in head and neck reconstruction surgeries [3].

This paper consists in a narrative review of the anatomical and epidemiological aspects of the sternalis muscle. We also present the

finding of this anatomical variation in one of the dissections performed by this research team from the Faculty of Medicine of the University of São Paulo (FMUSP).

## Method

The study is a narrative review of the anatomical and epidemiological aspects of the sternalis muscle. We also describe the finding of this anatomical alteration in one of our dissections.

The literature review used the search terms “{[(sternalis muscle) OR (sternal muscle)] AND [(anatomy) or (variation)]}” in both PubMed and Latin American and Caribbean Health Sciences Literature (LILACS) platforms. The inclusion criteria used were articles from 1987 to 2022, ranging from the oldest articles found in those search engines to the date of the actual search. Focused on epidemiological and anatomical aspects, and written in English, Portuguese, or Spanish. Exclusion criteria were articles focusing on radiological aspects or surgical approaches to the muscle.

The search results were analyzed by at least one of the authors. Articles were fully read after applying inclusion and exclusion criteria based on the title and abstract. Inclusion and

exclusion criteria were re-applied after the complete look through of the paper. The articles were then analyzed regarding the incidence and laterality of the sternalis muscle, as well as its characteristics of action, innervation, and vascularization. Data processing was performed to calculate frequencies and percentages of incidence using the Microsoft Excel 2013 program.

Our case report consists of the findings during dissections in the head and neck region in cadavers from the death verification service (SVO) of the HCFMUSP. These dissections are performed weekly by our research team, under the registered number 2022/7231. Such dissections consist of a bi-acromial incision, followed by planes dissection up to the platysma muscle, then a subsequent detachment of the platysma muscle up to the cervical region with dissection of the superficial fascia, and exploration of the anterior neck structures.

## Results

Using the descriptors mentioned for this review we found a total of 79 articles in the PubMed platform and 14 in LILACS, totalizing 93 articles. After reading the titles and abstracts, 31 articles were included for full reading, of which

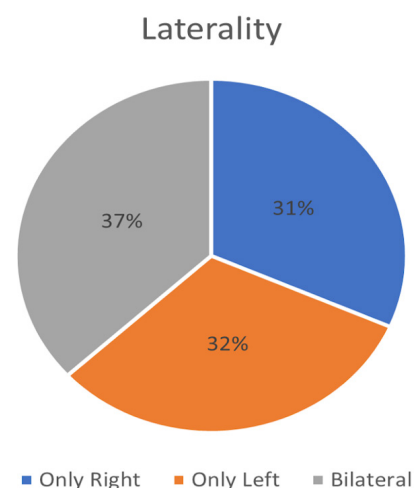
nine (9) articles were afterwards excluded.

Our review included 22 articles, 18 in English, two in Portuguese and two in Spanish [1-22]. Of the articles included, four (18.18%) were randomized studies [1,5,6,11] 12 (54.54%) were case reports [2,3,7-10,12-14,17,18,20], and six (27.27%) were literature reviews [4,6,15,19,21,22].

Table 1 shows the major incidences of this anatomical variant identified according to the four randomized studies included in this article. Figure 1 shows the laterality distribution according to the descriptions of case reports and case series. Two articles mention the actions of the sternal muscle, which is attributed to the function of raising the costal arches, therefore contributing to the ventilation [5,6]. Seven articles address the sternal muscle innervation. Four of them mention the innervation as being performed by more than one nerve [5-9] and three articles attribute it to a single nerve [1,3,10]. The nerve most commonly cited is the intercostal nerve. The different innervations observed by the authors are documented in table 2. None of the articles used for this review have information about the vascularization of the sternalis muscle.

**TABLE 1**  
**Incidence in Randomized Study Articles.**

Author	Country	Number of cases	Laterality
Silveira et al. 2012	Brazil	2/102 (1,96%)	Only Left
Sonne 2020	USA	2/36 (5,55%)	Bilateral
Katara et al. 2013	India	1/30 (3,33%)	Only Right
Vaithianathan et al. 2011	India	1/25 (4%)	Bilateral



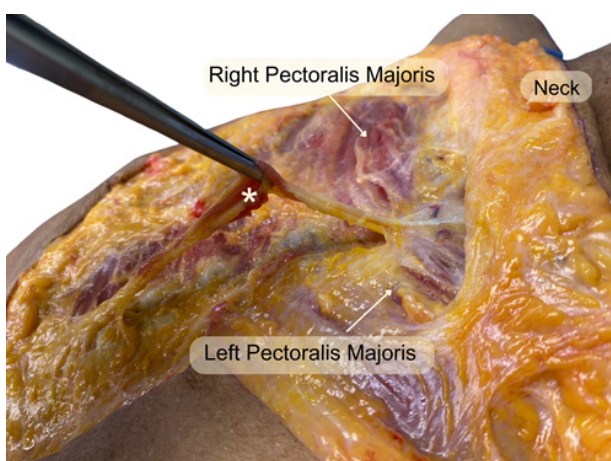
**Figure 1)** Frequency of Sternal Muscle Laterality in the evaluated studies.

**TABLE 2****Innervation of the Sternal Muscle.**

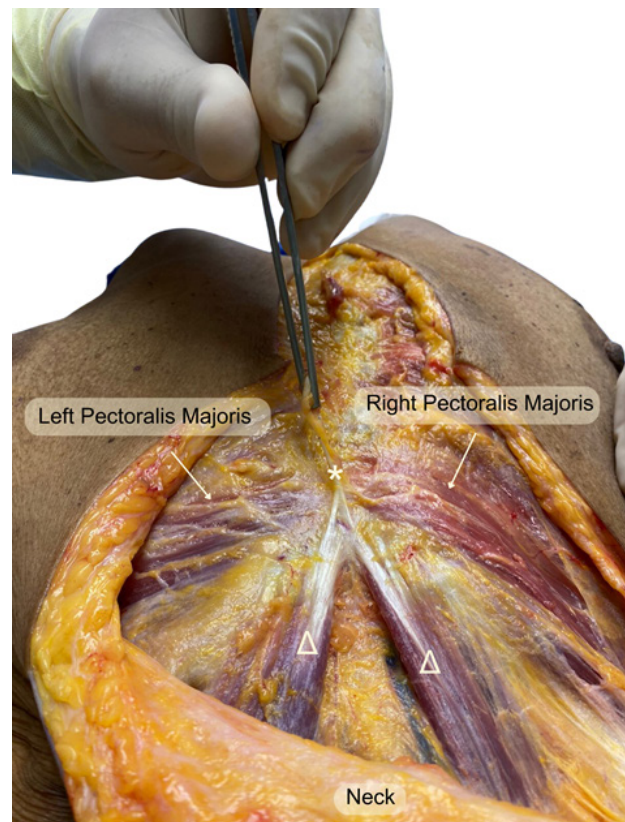
	Intercostal Nerves	Cutaneous Nerve	Pectoral Nerve	Thoracic Nerves
Katara et al. 2013	X		X	
Anjamrooz. 2013		X		X
Arráez-Aybar et al. 2003	X	X		
Awad et al. 2021		X		
Vaithianathan et al. 2011	X			
Kumar et al. 2003			X	
Pillay et al. 2016	X		X	

Among the randomized studies and case reports analyzed, fifteen out of twenty-two articles described the sex of the cadaver with sternalis muscle. In all, 204 cadavers were included, of which 18 individuals had the referred structure, 13 were male and five were female.

In our dissection, we found the presence of the rectus sternalis muscle in a black, 83-year-old female cadaver, with bronchopneumonia as the cause of death. We observed a sternalis muscle with insertion on both sternocleidomastoid muscles, situated unilaterally, in the left side, as shown in figures 2 and 3.



**Figure 2)** View from the side of patients lower neck and upper chest. Sternalis Muscle (\*) in evidence, being pulled.



**Figure 3)** View from patients chest, with camera angled at patients head. Both sternocleidomastoid muscles (Δ) are in evidence, showing their relation to the single sternalis muscle (\*).

## Discussion

The main finding of the present article was that the incidence of sternalis muscle in randomized studies ranged from 1.96% [11] to 5.55% [6], with a bilateral presentation of the muscle being more prevalent than the unilateral one. The prevalence of the sternalis muscle among male individuals was higher than in females. These

findings were similar to the incidences presented in the case reports analyzed in this review, but differed from the consolidated literature [2]. The difference in incidence by sex presented here may have been due to the intrinsic rarity of the existence of this muscle in human beings, the small number of articles that evaluated the incidence in a randomized and prospective way, or it may be due to the intrinsic social issue in our reality, where the male sex is more likely to serve as an object of an anatomical study of post-mortem dissection.

In our dissection, we found a unilateral left sternalis muscle that inserted into both sternocleidomastoid muscles, which was different from what is more frequently reported in the literature. Moreover, case reports and literature reviews differ from each other and bring into their discussions the difficulty of concluding a pattern for this structure [3,5,8-10]. Similarly, vascularity is not a consensus in the current literature and is not addressed in the case reports and the randomized studies we evaluated [3,5,8-10]. The innervation of the sternal muscle is also poorly defined, but researchers argue that both pectoral nerve and the intercostal nerve may play a role in its

innervation, and some authors argue that the thoracic nerves may also be responsible for this muscle innervation [3,7,13]. Its functions are accessory [5,6] to ventilatory muscles, helping in the elevation of the lower ribs.

The resection of the sternalis muscle not present risks, however, familiarization with this structure as to its location and possible insertion increases the chances of its early identification during mastectomies and thoracic and head and neck procedures, allowing its correct dissection and minimizing potential mistakes with other structures.

## Conclusion

The sternalis muscle has a small incidence Brazilian, Indian and American population, and when present, it is usually bilateral. Its importance cannot be neglected due to possible misinterpretations in imaging exams and its possible influence on mastectomies, depending on its morphology. Furthermore, it is a useful anatomical variation for performing head and neck flaps in reconstruction surgeries. Larger case series are necessary for a better definition of its irrigation and innervation.

---

## References

1. Vaithianathan G, Aruna S, Rajila RH, et al. Sternalis “mystery” muscle and its clinical implications. *Ital J Anat Embryol.* 2011;116:139-43.
2. Kabay B, Akdogan I, Ozdemir B, et al. The left sternalis muscle variation detected during mastectomy. *Folia Morphol (Warsz).* 2005;64:338-40.
3. Awad KA, Ahmed GE, Al-Lah QAA, et al. Bilateral sternalis muscle in a Sudanese cadaver. *Int J Surg Case Rep.* 2021;89:106511.
4. Oliveira LA, Quintana HT, Oliveira F. Importância clínica do músculo esternal e suas variações anatômicas: uma revisão sistemática da literatura. *ABCS Health Sci.* 2017;42:93-8.
5. Katara P, Chauhan S, Arora R, et al. A unilateral rectus sternalis muscle: rare but normal anatomical variant of anterior chest wall musculature. *J Clin Diagn Res.* 2013;7:2665-7.
6. Sonne JWH. Prevalence of the sternalis muscle in a sample of routinely dissected human cadavers. *Surg Radiol Anat.* 2020;42:87-90.

7. Anjamrooz SH. Biceps sternalis: a Y-shaped muscle on the anterior chest wall. *J Cardiothorac Surg.* 2013;8:38.
8. Pillay M, Ramakrishnan S, Mayilswamy M. Two Cases of Rectus Sternalis Muscle. *J Clin Diagn Res.* 2016;10:AD01-3.
9. Arráez-Aybar LA, Sobrado-Perez J, Merida-Velasco JR. Left musculus sternalis. *Clin Anat.* 2003;16:350-4.
10. Kumar H, Rath G, Sharma M, et al. Bilateral sternalis with unusual left-sided presentation: a clinical perspective. *Yonsei Med J.* 2003;44:719-22.
11. Silveira D, Sousa LM, Siqueira SL, et al. Sternalis muscle: an anatomic variation of the anterior chest wall. *J Morphol Sci.* 2012;29:76-8.
12. Davimes JG, Bacci N, Mazengenya P. Evidence of the sternalis muscle in two South African cadavers. *Surg Radiol Anat.* 2018;40:1313-7.
13. Akyurek U, Caragacianu D, Akyurek M. Sternalis is muscle: an anatomic variation and its clinical implications. *J Plast Reconstr Aesthet Surg.* 2020;73:2084-5.
14. Raikos A, Paraskevas GK, Tzika M, et al. Sternalis muscle: an underestimated anterior chest wall anatomical variant. *J Cardiothorac Surg.* 2011;6:73.
15. Snosek M, Tubbs RS, Loukas M. Sternalis muscle, what every anatomist and clinician should know. *Clin Anat.* 2014;27:866-84.
16. Raikos A, Paraskevas GK, Yusuf F, et al. Sternalis muscle: a new crossed subtype, classification, and surgical applications. *Ann Plast Surg.* 2011;67:646-8.
17. Coskun N, Yildirim FB, Ozkan O. Multiple muscular variations in the neck region-case study. *Folia Morphol (Warsz).* 2002;61:317-9.
18. Natsis K, Vlasis K, Totlis T, et al. An unusual bilateral sternalis muscle. *Chirurgia (Bucur).* 2008;103:231-2.
19. Poveda CA, Munoz EJ, Camargo DC. Músculo esternalis: variante anatómica que simula neoplasia em mamografia. *Rev Colomb Cancerol.* 2013;17:46-9.
20. Marques EF, Souza JA, Graziano L, et al. Sternalis muscle simulating a breast nodule. *Rev Bras Ginecol Obstet.* 2009;31.
21. Scott-Conner CE, Al-Jurf AS. The sternalis muscle. *Clin Anat.* 2002;15:67-9.
22. Kida MY, Izumi A, Tanaka S. Sternalis muscle: topic for debate. *Clin Anat.* 2000;13:138-40.