

## CASE REPORT

# The Ongoing Myth of TIPIC-Syndrome

Croo Alexander<sup>1\*</sup>, Van Lierde Katrien<sup>2</sup>,  
Van Offel Steven<sup>3</sup>, Beeckman Sam<sup>3</sup>, Vereecke Elke<sup>4</sup>

Croo A, Katrien VL, Steven VO, et al. **The Ongoing Myth of TIPIC-Syndrome. Int J Endovasc Treat Innov Tech. 2022;3(1):1-5.**

## Abstract

Carotidynia is characterized by intense localized pain and tenderness at the level of the carotid bifurcation. The differential diagnosis is broad and includes vascular pathologies, infectious diseases or malignancies. Recent evidence now suggests a distinct entity called Transient

Perivascular Inflammation of the Carotid Artery or TIPIC syndrome. The diagnosis is made per exclusionem and is based on typical radiological findings. This paper describes the clinical examination, laboratory results, radiological findings and treatment based on two case reports. TIPIC syndrome is an idiopathic syndrome which is usually a self-limiting disease of which a vascular surgeon should be aware.

**Key Words:** *Carotid artery; Neck pain; Carotidynia; Inflammation*

## Introduction

Carotidynia was first described by Fay in 1927 as localized pain and tenderness at the level of the carotid bifurcation [1]. It was defined in the first International Classification of Headache Disorders (ICHD) in 1988, but removed as a distinct entity in 2004 due to disputed evidence regarding diagnostic criteria [2,3]. The differential diagnosis includes carotid artery dissection or aneurysm, vasculitis, cervical arthrosis, sialadenitis, thyroïditis, head and neck tumours or infectious diseases. Based on

typical radiological findings, recent evidence now suggests a distinct clinical entity called Transient Perivascular Inflammation of the Carotid Artery or TIPIC syndrome [4-9]. TIPIC was first described as a separate entity by Lecler et al in 2017 [5]. It is characterised as acute onset unilateral tenderness near the carotid artery with distinct radiological findings. It is believed to be caused by transient inflammation of the vessel wall and the peri carotid tissues, however the exact pathogenesis is poorly understood [5-6]. Current evidence and published data on prevalence are scarce.

<sup>1</sup>Department of thoracic and vascular surgery, Ghent university hospital, Ghent, Belgium

<sup>2</sup>Department of emergency medicine, Ghent university hospital, Ghent, Belgium

<sup>3</sup>Department of rheumatology, Ghent university hospital, Ghent, Belgium

<sup>4</sup>Department of radiology, Ghent university hospital, Ghent, Belgium

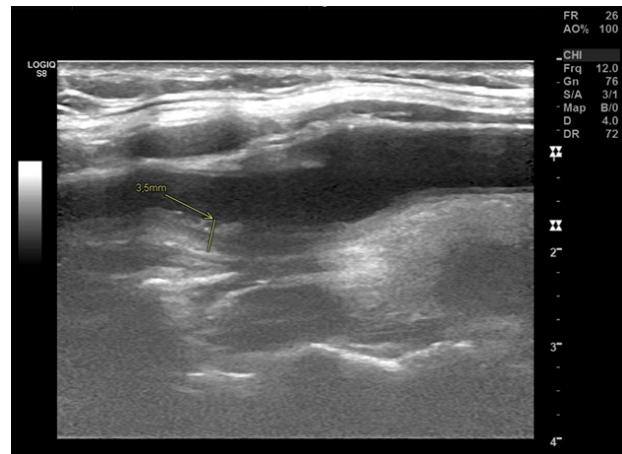
\*Corresponding author: Croo Alexander, Thoracic and vascular surgery fellow, Department of thoracic and vascular surgery, Ghent university hospital, Ghent, Belgium, Tel: 0032.9/332.55.26; E-mail: alexandercroo@gmail.com

Received: September 15, 2022, Accepted: November 05, 2022, Published: November 23, 2022



## Case 1

A 47-year-old female presented at the emergency department with complaints of right-sided sharp pain in the neck, radiating to the right ear and fatigue for 3 days. She denied difficulties with swallowing, sore throat or any difficulty breathing. She already tried piroxicam, not relieving the complaints and a single dose of ibuprofen, relieving her symptoms slightly. Clinical examination revealed a tender swelling lateral to the thyroid gland without adenopathies. Clinical neurological and cardiovascular examination were normal. Medical history only withholds a cold thyroid nodule diagnosed 4 years earlier. She did not take any medication. Blood tests showed normal white blood cell count, normal erythrocyte sedimentation rate, C-reactive protein (CRP) of 5.5 mg/L (normal value <5 mg/L) and a normal thyroid-stimulating hormone. Ultrasonography mentioned the known thyroid nodule and a remarkable thickening of the right carotid wall at the level of the carotid bifurcation with infiltration of perivascular fatty tissue, but without any signs of dissection or intramural hematoma. Contrast-enhanced CT scan showed wall thickening and infiltration of the perivascular fatty tissue surrounding the distal common carotid artery, the carotid bifurcation, and the proximal part of the internal and external carotid artery. The patient was treated with paracetamol and Ibuprofen. Outpatient follow-up after six weeks revealed no remaining complaints. Additional rheumatological examination did not withhold any evidence of underlying vasculitis or autoimmune diseases with normal ANA, Anti-Ro/SSA and ANCA (Figure 1).

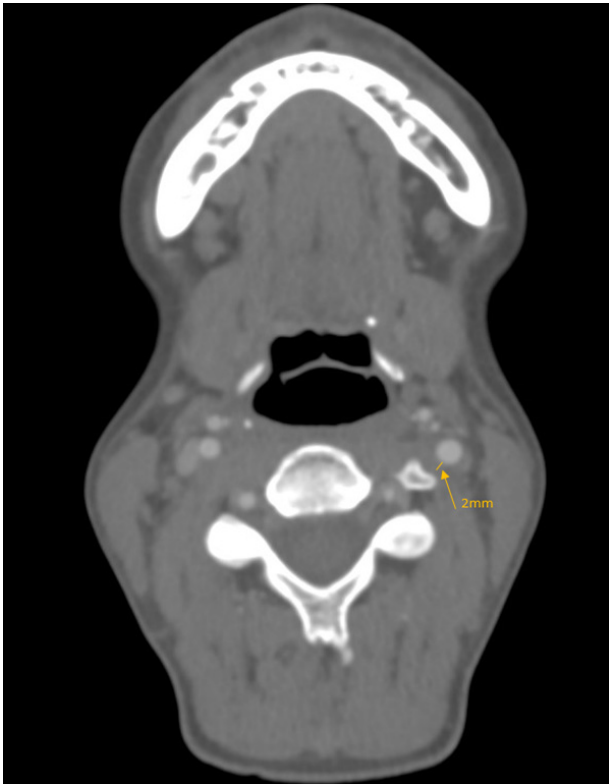


**Figure 1)** Sagittal ultrasound image of the right common carotid artery, carotid bulb, and proximal internal carotid artery, demonstrating thickening of the carotid wall and perivascular soft tissues up to 3.5 mm, with minimal luminal narrowing.

## Case 2

A 38-year-old female presented at the emergency department after referral by a radiologist because of a heterogenous aspect and hyperemia of the thyroid gland and focal thickening of the left distal common carotid artery and carotid bifurcation on ultrasound. She had complaints of left-sided neck pain for 6 days, especially when moving the neck and a localized tenderness below the left mandible. She denied any other neurological or cardiovascular symptoms, had no sore throat or difficulties swallowing or breathing. Clinical examination showed localized tenderness when palpating the distal carotid artery and a localized swelling. Clinical neurological and cardiovascular examination were normal. Medical history was unremarkable. Blood tests were normal: normal white blood cell count, normal CRP and an erythrocyte sedimentation rate of 21 mm/u (normal range 0-20 mm/u). CT angiography demonstrated thickening of the left carotid wall and perivascular soft tissues

with minimal luminal narrowing. Follow-up by a rheumatologist showed complete resolution of symptoms after treatment with paracetamol and diclofenac for 4 days. No evidence of an underlying vasculitis or auto-immune diseases was found. ANA, Anti-Ro/SSA and ANCA were all normal (Figure 2).



**Figure 2)** CT-angiography at the level of the left internal carotid artery demonstrating eccentric thickening of the carotid wall and perivascular soft tissues up to 2 mm with mild luminal narrowing.

## Discussion

TIPIC syndrome presents as an intense, sharp, and most often unilateral neck pain with pronounced localized tenderness around the carotid bifurcation. Up to 4% of bilateral involvement has been reported. There seems to be a slight female predominance and a possible association with autoimmune diseases, like Hashimoto thyroiditis, Graves' disease, Sjogren syndrome, systemic lupus erythematosus, rheumatoid arthritis or ankylosing spondylarthritis. Lecler

et. al. reported that patients with an underlying autoimmune disease presenting with TIPIC frequently experienced a relapse of their underlying disease. Although TIPIC syndrome is considered a self-limiting disease, 19% of the patients may experience a relapse [5].

Associated neurologic symptoms such as dizziness, vertical diplopia, ipsilateral peripheral facial palsy, contralateral dysesthesia and even contralateral transient motor deficit have been reported. In the series of Lecler et al. all patients with neurologic events (17%) underwent MR imaging which did not reveal any brain abnormalities. A possible explanation for this relationship remains unknown. One hypothesis that has been proposed is simultaneous inflammation of both carotid and intracranial arteries [5].

The pathogenesis is poorly understood. TIPIC syndrome is characterised by transient inflammation of the vessel wall, mainly in the adventitia and the perivascular tissues [5,6,10]. Upton et al. first described the histological changes in TIPIC syndrome as non-specific inflammatory changes including vascular proliferation, proliferation of fibroblasts and low-grade chronic active inflammation, all limited to the adventitia of the carotid artery [10]. Ipsilateral lymph node enlargement or contiguous pharyngolaryngeal inflammation have also been reported [11].

Typically, an eccentric perivascular inflammation around the carotid bifurcation can be found on ultrasound, CT or MRI. Lecler et al. reported a median diameter of 5 mm and a median span of 20 mm of perivascular inflammation. In up to 50% of patients a self-limiting, intimal soft

plaque was found. It is assumed that these intimal changes might be induced by the healing phase of the carotid inflammatory process. A mild lumen narrowing without haemodynamic changes may be observed [5]. In patients with associated neurological symptoms or in doubtful cases additional imaging with MRI or CT angiography is required to rule out other differential diagnoses [4-9]. Although symptoms usually resolve within 2 weeks, persistence of imaging abnormalities is reported in recent literature, possibly related to the development of fibrosis associated with low-grade chronic inflammation, as described by Upton et al., [10]. The hypothesis of a secondary development of atherosclerosis might justify follow-up with ultrasound.

Blood tests are usually of limited value in confirming the diagnosis, as only a minority of the patients show mildly elevated inflammatory markers, such as erythrocyte sedimentation rate or CRP [5]. As TIPIC syndrome is considered a diagnosis of exclusion, blood tests are useful in ruling out alternative causes of atypical neck pain, such as thyroiditis, or confirming an underlying autoimmune disease. To date, there are no specific treatment guidelines for TIPIC syndrome. Most cases seem to respond well to anti-inflammatory treatment with NSAIDs and report complete resolution of symptoms within 14 days. A minority of the patients may have recurring symptoms. In these cases, it seems advisable to rule out autoimmune diseases [4,5,7].

In 2017, Lecler et al. proposed following

diagnostic criteria to be added to the International Classification of Headache Disorders:

- Major criteria: presence of acute pain overlying the carotid artery, which may or may not radiate to the head, eccentric perivascular inflammation on imaging, exclusion of another vascular or nonvascular diagnosis with imaging or improvement within 14 days either spontaneously or with anti-inflammatory treatment.
- Minor criterion: presence of a self-limited intimal soft plaque [5].

Thirty years after the first ICHD, the latest version of 2018 did not acknowledge TIPIC as a separate entity. Consequently, the myth of TIPIC-syndrome remains ongoing.

## **Conclusion**

TIPIC syndrome is a self-limiting disease of which vascular surgeons should be aware when treating patients with intense neck pain near the carotid artery. The diagnosis is made per exclusionem and is based on the radiological finding of an eccentric perivascular inflammation of the carotid bifurcation. Blood tests and imaging studies can be useful in ruling out other differential diagnoses. Symptoms usually disappear after treatment with NSAIDs. Although the evidence is scarce, ruling out underlying autoimmune diseases is recommended, especially in patients with recurring symptoms. As the literature on TIPIC syndrome remains scarce, reporting all cases in literature is advisable.

## References

1. Fay T. Atypical neuralgia. *Arch Neurol Psychiatry*. 1927;18:309-15.
2. Headache Classification Committee of the International Headache Society. Classification and diagnostic criteria for headache disorders, cranial neuralgias and facial pain. *Cephalalgia*. 1988;8:1-96.
3. Headache Classification Subcommittee of the International Headache Society. The international classification of headache disorders 2nd edition. *Cephalalgia* 2004;24:9-160.
4. Abraham M, Werner M, Gottlieb P. et al. Ultrasound for the diagnosis of carotidynia. *J Ultrasound Med*. 2017;36:2605-9.
5. Lecler A, Obadia M, Savatovsky J. et al. TIPIC Syndrome: beyond the myth of carotidynia, a new distinct unclassified entity. *Am J Neuroradiol*. 2017;38:1391-8.
6. Ulus S, Ozcan UA, Arslan A. et al. Imaging spectrum of TIPIC syndrome: Validation of a new entity with vessel wall imaging. *Clin Neuroradiol*. 2020;30:145-57.
7. Coulier B, Van den Broeck S, Colin GC. Carotidynia alias transient perivascular inflammation of the carotid artery (TIPIC Syndrome). *J Belg Soc Radiol*. 2018;102:50.
8. Scoppettuolo P, Dalaqua M, Ghika JA. et al. Multimodal imaging for a TIPIC syndrome case. *Acta Neurol Belg*. 2021.
9. Skalla E, Loizides A, Plaikner M. et al. Segmental carotid wall thickening in tipic syndrome: Is the depiction of microvascularity the key to determining activity? *Ultraschall Med*. 2021;42:92-3.
10. Upton PD, Smith JG, Charnock DR. Histologic confirmation of carotidynia. *Otolaryngol Head Neck Surg*. 2003;129:443-4.
11. Comacchio F, Bottin R, Brescia G. et al. Carotidynia: new aspects of a controversial entity. *Acta Otorhinolaryngol Ital*. 2012;32:266-9.